

## Hydroxyurea for treatment of unresectable and recurrent meningiomas. II. Decrease in the size of meningiomas in patients treated with hydroxyurea

UWE M. H. SCHRELL, M.D., MICHAEL G. RITTIG, M.D., MARC ANDERS, UWE H. KOCH, PH.D., ROLF MARSCHALEK, PH.D., FRANKLIN KIESEWETTER, M.D., AND RUDOLF FAHLBUSCH, M.D.

*Departments of Neurosurgery, Anatomy, Dermatology, and Genetics, University of Erlangen-Nürnberg, Erlangen, Germany*

✓ In this paper the authors present the first evidence that meningiomas respond to treatment with hydroxyurea. Hydroxyurea was administered as an adjunct chemotherapeutic treatment in patients with recurrent and unresectable meningiomas. Hydroxyurea was used because experimental data demonstrated that it inhibits growth of cultured human meningioma cells and meningioma transplants in nude mice by inducing apoptosis. The authors therefore treated four selected patients with hydroxyurea. All patients had undergone multiple gross resections and all except one received radiotherapy. Three patients with recurrent Grade I meningiomas assessed according to World Health Organization (WHO) guidelines received hydroxyurea because of an increased tumor growth rate, documented by magnetic resonance (MR) imaging, within a 6- or 12-month interval. A fourth patient with a malignant meningioma (WHO Grade III) began a course of treatment with hydroxyurea immediately after his sixth palliative operation without waiting for another relapse to be demonstrated on MR imaging. Because of their location and invasive growth behavior none of the meningiomas could have been removed completely by surgical intervention.

All patients received hydroxyurea at a dosage level of 1000 to 1500 mg/day (approximately 20 mg/kg/day). In a man with a large sphenoid wing meningioma invading the right cavernous sinus and the temporal base, the intracranial tumor mass was reduced by 60% during 6 months of treatment. A woman with a large ball-shaped meningioma of the right sphenoid wing invading the cavernous sinus exhibited a 74% decrease of the initial tumor volume in 10 months of treatment with oral hydroxyurea. Serial MR images obtained monthly revealed that the process of size reduction was continuous and proportionate. The shrinkage of the tumor was accompanied by a complete remission of symptomatic trigeminal neuralgia after 2 months and by improved abducent paresis after 5 months. The third patient had a slowly growing meningioma that exhibited a 15% reduction in mass when reassessed after 5 months of hydroxyurea treatment. The fourth patient with the malignant meningioma in the left cerebellopontine angle has had no recurrence for 24 months. Long-term treatment with hydroxyurea may result in full remission of tumors in meningioma patients.

The preliminary data indicate that hydroxyurea provides true medical treatment in patients with unresectable and recurrent meningiomas, replacing palliative surgery and radiotherapy in the management of this disease.

**KEY WORDS • hydroxyurea • chemotherapy • meningioma • nonglial brain tumor • adjunct therapy • growth inhibition • apoptosis**

**M**ENINGIOMAS are solid tumors of mesodermal origin that appear as intracranial and intraspinal tumors. According to the World Health Organization (WHO) grading system<sup>35</sup> most meningiomas are Grade I (benign), whereas Grades II and III (malignant) meningiomas account for about 7%<sup>23</sup> of cases. Although the primary treatment is surgical, complete resection is often impossible because of the extent of osseous tumor invasion or the tumor penetration into the connective tissue of the cavernous sinus, which causes functional deficits by compression of and infiltration into the optic and motor nerves and the wall of the internal carotid artery.<sup>7,19,21</sup> Permanent cranial nerve dysfunction may be a consequence of total and radical tumor resection in this region.

The surgical concept of total removal of cavernous sinus meningiomas has lost favor because of high mor-

bidity combined with a high recurrence rate.<sup>3,10,15,18,33</sup> Therefore the current treatment strategy is less aggressive, aiming at decompression<sup>15,18</sup> and radiotherapy in progressive tumors.<sup>22,26</sup> Although radiotherapy only rarely achieves a true tumor mass reduction, it can arrest growth in malignant as well as benign meningiomas for some years.<sup>2,4,9,12,14,24,27</sup>

The concept of an adjunct medical treatment using glucocorticoids and their antagonists for unresectable meningiomas has been explored since the late 1970s.<sup>6,11,28-30</sup> However, none of these drugs, including the progesterone antagonist RU-486, was efficient in controlling tumor proliferation in meningioma patients, although initial minor responses in tumor regression have been reported.<sup>16,20</sup>

The use of systemic chemotherapy for treatment of malignant meningiomas has been reported recently.<sup>8</sup> This treatment regimen (adjuvant radiotherapy followed by

# Treatment of recurrent meningioma by hydroxyurea

TABLE 1

Summary of clinical characteristics and results of hydroxyurea treatment in four patients with unresectable and recurrent meningiomas

Case No.	Age (yrs), Sex	Epidemiological Data			Prior Management				Response to Hydroxyurea Therapy*		
		Histological Findings	WHO Grade	Site of Tumor	No. of Ops	Radiotherapy	Last Palliative Surgery	Progression (%)†	Follow-Up Interval (mos)	Tumor Reduction (%)	Improvement of Symptoms
1	46, M	meningotheliomatous (fibrous)	I	sphenoid wing, cavernous sinus, temporal fossa	2	5 yrs	1.3 yrs	>50	6 13	60 75	NA
2	47, F	meningotheliomatous (angiomatous)	I	sphenoid wing, cavernous sinus	1	none	3.5 yrs	>50	5 10	53 74	cure of symptomatic trigeminal neuralgia & improved paresis of cranial nerve VI
3	44, F	meningotheliomatous (angiomatous)	I	cavernous sinus	1	1.5 yrs	2.5 yrs	<30	5	15	cure of symptomatic trigeminal neuralgia
4	56, M	anaplastic formerly meningo-theliomatous	III I	posterior fossa, cerebellopontine angle	6	5 yrs	1 mo	NA	24	tumor free	NA

\* Patients received no other medications after initiation of hydroxyurea therapy. Abbreviation: NA = not applicable.

† Rate of regrowth occurring within 1 year of last palliative surgery. Progression did not occur in Case 4 because hydroxyurea treatment was instituted within 1 month of the patient's last palliative surgery. The percentage of tumor progression between the fifth and sixth surgeries (8 months) was more than 100%.

cycles of cyclophosphamide, adriamycin, and vincristine) did not produce better results than adjuvant radiotherapy alone. Because of their toxicity, these chemotherapeutic agents can be applied only once, in therapeutic cycles lasting a few weeks.

In contrast, our concept is based on long-term (over years) chemotherapeutic treatment taking into account that meningiomas are slowly growing tumors with a low mitotic index. Therefore, we tested the effects of various low morbidity-causing chemotherapeutic drugs on human meningioma cell growth in vitro. The selected agent was hydroxyurea. This chemotherapeutic drug drastically inhibits the growth of human meningioma cells and meningioma transplants in nude mice by triggering the apoptotic cascade.<sup>31,32</sup>

This is the first report of a successful use of hydroxyurea in the medical treatment of unresectable and recurrent benign as well as malignant meningiomas.

## Clinical Material and Methods

### Patient Eligibility Criteria

This study was designed to evaluate the efficacy and side effects of hydroxyurea as an adjunct therapy in meningioma patients. Patients with recurrent and unresectable intracranial meningiomas were eligible for this study. In all cases with remnants of solid meningioma, the tumor had either grown into the cavernous sinus or originated from that site. Patients who had received prior cranial radiation treatment were also eligible if the tumor had shown radiologically documented progression following irradiation. Because hydroxyurea decreases hematological values, adequate hematological reserves (white blood cell count > 3000/ $\mu$ l [normal value 4000–10,000/ $\mu$ l], platelet count > 100,000/ $\mu$ l), hepatic reserves (bilirubin < 2 mg%), and renal reserves (creatinine < 2 mg%) were required. Patients were deemed ineligible if there was evidence of a second active neoplasm requiring cytotoxic chemotherapy, a serious intercurrent illness, or a history of thrombophlebitis.

### Patient Characteristics

Four patients, two women and two men, ranging in age from 44 to 56 years (mean 48 years) were included in this study (Table 1). Both women were postmenopausal. All patients were ambulatory adults with a Karnofsky Performance Scale rating of greater than 70%.

In each case the diagnosis of meningioma was based on histological evaluation. The tumor histology was meningotheliomatous, WHO Grade I in three patients, with an angiomatous component in two cases and a fibrous component in one. One male patient had a malignant meningioma (WHO Grade III). All patients had undergone surgical procedures previously; two had undergone multiple attempted complete resections of recurrent meningiomas over a period of 4 and 9 years, respectively, the latter with progression from a Grade I meningotheliomatous meningioma to a Grade III malignant meningioma. Because of the enhanced proliferative activity, a recurrent tumor had been documented by magnetic resonance (MR) imaging within 3 months of follow up, after his fourth and fifth operations. Three patients had previously received radiotherapy. Two patients had symptomatic trigeminal neuralgia, and one of them had abducent nerve paresis.

### Treatment Protocol and Follow-Up Period

Patients received a daily oral dosage of 1000 or 1500 mg of hydroxyurea supplied as 500-mg tablets, equal to 20 mg/kg/day, throughout the course of the study. The dosage was estimated not to lower the white blood cell count below 3000/ $\mu$ l. Hematological monitoring was performed by a general practitioner twice a week during the 1st month and once a week thereafter. Full blood counts and a selection of serum chemistry tests were obtained once a month. A complete physical and neurological examination was performed every 3 months and included evaluation for subjective side effects and improvement or worsening of clinical symptoms caused by the meningioma. Tumor measurement was assessed by MR imaging before treatment and every 3 months thereafter. In one patient MR images were obtained monthly.

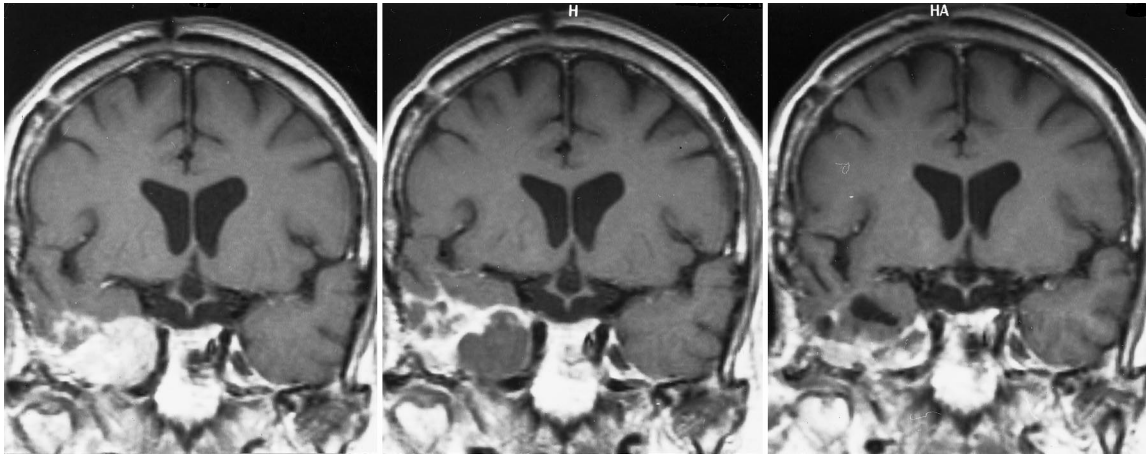


FIG. 1. Case 1. Coronal T<sub>1</sub>-weighted gadolinium-enhanced MR images. Note the infundibulum at the bottom of the third ventricle in all three panels revealing identical slice positions. *Left:* Pretreatment MR image revealing a large meningeoma of the right sphenoid wing invading the cavernous sinus and the right temporal base. *Center:* An MR image obtained 3 months after initiation of hydroxyurea treatment revealing the meningeoma in place and unchanged in size, but with a huge clearly demarcated hypointense area indicating a significantly reduced gadolinium uptake. *Right:* An MR image obtained 6 months after initiation of hydroxyurea treatment revealing a small tumor rim in the base of the right temporal fossa. The right temporal horn, which had been compressed by the tumor mass, is now unfolded. The intracranial tumor mass was reduced by 60%.

None of the patients received supplements of dexamethasone or other glucocorticoids.

### Results

#### Responses to Therapy

In this group of patients daily hydroxyurea therapy has been administered for periods ranging from 5 to 24 months and will be continued for a minimum of 2 years.

Before treatment all patients exhibited tumor progres-

sion within 1 year, as documented on MR imaging. During the course of treatment none of the patients has shown further growth of the tumor. The patient with the right-sided large sphenoid wing meningeoma infiltrating the cavernous sinus and the temporal base (Case 1) showed drastic tumor regression (60%) after 6 months of hydroxyurea treatment (Fig. 1). The patient with the extensive right-sided sphenoid wing meningeoma infiltrating the cavernous sinus and causing abducent nerve paresis and symptomatic trigeminal neuralgia (Case 2) also achieved

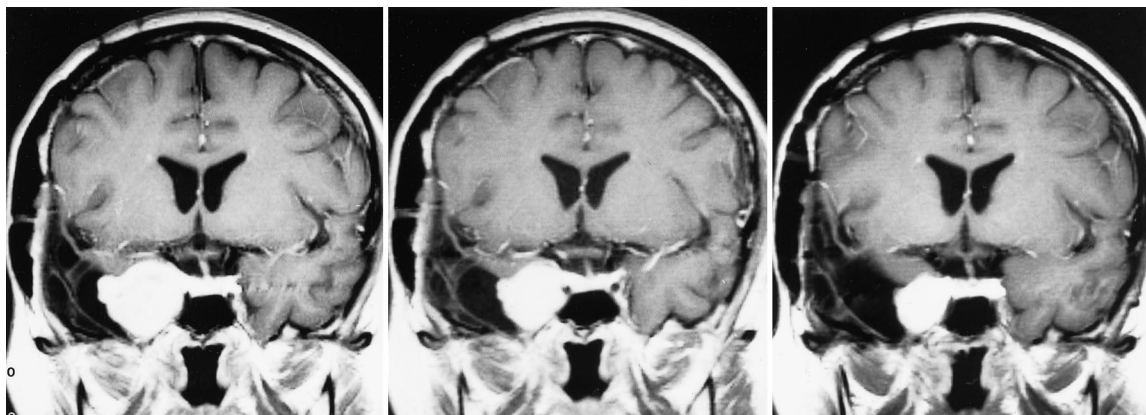


FIG. 2. Case 2. Coronal T<sub>1</sub>-weighted gadolinium-enhanced MR images. Note the pituitary stalk at the bottom of the third ventricle in all panels, revealing identical slice positions. *Left:* Pretreatment MR image revealing a large ball-shaped meningeoma of the right sphenoid wing invading the cavernous sinus. *Center:* An MR image obtained 5 months after initiation of hydroxyurea treatment, revealing the meningeoma in place but reduced in size by 53%. Note that even the small tumor satellite was reduced in size. *Right:* An MR image obtained 10 months after initiation of hydroxyurea treatment, revealing the meningeoma in place but reduced in size by 74%. Note the similar configuration seen in *left* and *right* panels. The tumor mass was reduced proportionally as documented monthly by means of serial MR imaging (see Fig. 3).

## Treatment of recurrent meningioma by hydroxyurea

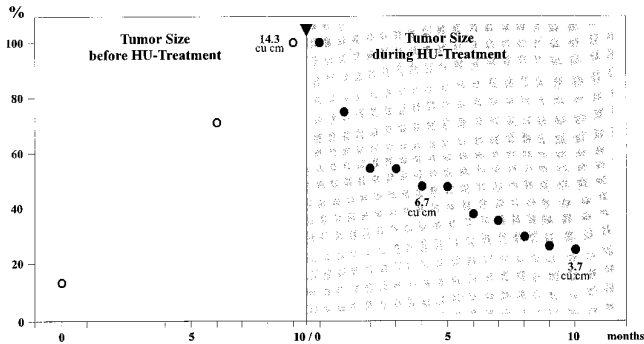


FIG. 3. Case 2. Graphs based on serial T<sub>1</sub>-weighted gadolinium-enhanced cortical MR images. The patient was examined before and at monthly intervals during hydroxyurea (HU) treatment. The graphs clearly demonstrate a continuous proportional reduction in tumor size. The arrowhead marks the initiation of HU treatment. *Left:* Graph showing growth rate of the meningioma before treatment. Tumor volume was calculated as 14.3 cm<sup>3</sup> (100%) at the beginning of HU treatment. *Right:* Graph showing growth rate during HU treatment. Tumor volume after 5 months of treatment was 6.7 cm<sup>3</sup> (47%), corresponding to a 53% reduction in size; after 10 months it was 3.7 cm<sup>3</sup> (26%), corresponding to a 74% reduction in size.

a dramatic decrease in tumor mass (74%) after 10 months of treatment. This tumor regression was documented monthly on serial MR images (Figs. 2 and 3). The shrinkage of the tumor was accompanied by a complete remission of the trigeminal neuralgia after 2 months and by improved extraocular muscle function after 5 months of treatment. Another patient with a slowly growing left-sided cavernous sinus meningioma (Case 3) and symptomatic trigeminal neuralgia achieved a minor decrease in tumor size (15%) and remission of her neuralgia after 5 months of treatment. The patient with the malignant Grade III meningioma in the left posterior fossa (cerebellopontine angle, Case 4), who was treated with hydroxyurea immediately after his sixth palliative operation without awaiting his next relapse, has not experienced recurrence during the 24-month course of hydroxyurea therapy.

### Toxicity and Side Effects

None of the patients had any problematic side effects. The maximum dose did not exceed 20 mg/kg/day, and was well tolerated. With respect to hematological toxicity, none of the patients experienced significant bone marrow suppression. If the white blood cell count fell below 3000/ $\mu$ l the dose was reduced for a few days. The most common nonhematological side effects were mild fatigue in two, bleeding of the gums in three, and constipation in two patients.

### Discussion

It has been demonstrated in this pilot study that hydroxyurea can reduce the size of intracranial meningiomas within 6 months. A chemotherapeutic regimen for intracranial meningiomas associated with such a dramatic

cytoreductive effect has not been reported previously. As expected, hydroxyurea acts more efficiently as a chemotherapeutic drug in rapidly than in slowly proliferating meningiomas. The therapeutic application for this agent ranges from benign (WHO Grades I and II) to malignant (WHO Grade III) meningiomas.

Radical surgical treatment of meningiomas causes high morbidity rates, which is evident in cavernous sinus meningiomas. Even totally resectable tumors such as convexity meningiomas have a median recurrence rate as high as 10% after 5 years, 20% after 10 years, and 50% after 20 years.<sup>1,23,25,34</sup> Recurrent meningiomas increase the morbidity and mortality rates of the patients. The likelihood of premature death in patients with Grade I and II lesions who undergo subtotal tumor removal is 4.2 times higher than in those who undergo total tumor removal and is comparable to patients with Grade III meningiomas (4.6 times higher).<sup>17</sup> Even adjunct radiotherapy only delayed regrowth or recurrence for a few years.<sup>4,27</sup>

The risks and limitations of surgery and fractionated radiotherapy are well known and despite years of investigation, cytotoxic and hormonal chemotherapy have not proven particularly beneficial.<sup>5,8,16,20</sup> The high rates of morbidity and mortality necessitate a more effective therapy and justify chemotherapeutic treatment of unresectable and recurrent meningiomas. Because most meningiomas are benign tumors bearing no biological features in common with carcinomas,<sup>35</sup> we considered chemotherapeutic drugs adapted to the biology of meningiomas. We selected hydroxyurea, which is used for long-term treatment of chronic myelogenous leukemia and is actually prescribed for permanent treatment of sickle cell anemia.<sup>13</sup> The decision to introduce hydroxyurea in the treatment of unresectable and recurrent meningiomas was ultimately based on our experimental findings in cell cultures and in tumor cell transplants in nude mice, which demonstrated that hydroxyurea stopped cell growth by triggering the apoptotic cascade.<sup>31,32</sup>

Hydroxyurea has never been used in the treatment of meningiomas and response rates of up to 70% within 1 year of initiation of oral administration reflect extraordinary success in the treatment of this solid tumor. By analogy with our experimental data,<sup>31,32</sup> we suggest that induction of apoptosis is also the cause of tumor regression in our patients. The activation of this mechanism gives hope that long-term treatment with hydroxyurea can lead to a true remission.

The preliminary clinical data presented in this report correlate in a fascinating way with our experimental data on meningioma biology and response to hydroxyurea, and justifies further study in a larger group of patients.

### Acknowledgments

We thank Mrs. Annemarie Gundler, Mr. Klaus-Jürgen Wolff, and all of the others who participated in this first trial study. We thank Dr. J. Wickboldt for referring the first patient. We appreciate the generous support of Dr. G. Moissl who performed the monthly MR imaging.

### References

1. Adegbite AB, Khan MI, Paine KWE, et al: The recurrence of intracranial meningiomas after surgical treatment. *J Neurosurg* 58:51-56, 1983

2. Al-Mefty O, Kersh JE, Routh A, et al: The long-term side effects of radiation therapy for benign brain tumors in adults. **J Neurosurg** **73**:502–512, 1990
3. Al-Mefty O, Smith RR: Surgery of tumors invading the cavernous sinus. **Surg Neurol** **30**:370–381, 1988
4. Barbaro NM, Gutin PH, Wilson CB, et al: Radiation therapy in the treatment of partially resected meningiomas. **Neurosurgery** **20**:525–528, 1987
5. Bernstein M, Villamil A, Davidson G, et al: Necrosis in a meningioma following systemic chemotherapy. Case report. **J Neurosurg** **81**:284–287, 1994
6. Blankenstein MA, Blaauw G, Lamberts SW, et al: Presence of progesterone receptors and absence of oestrogen receptors in human intracranial meningioma cytosols. **Eur J Cancer Clin Oncol** **19**:365–370, 1983
7. Bonnal J, Thibaut A, Brotschi J, et al: Invading meningiomas of the sphenoid ridge. **J Neurosurg** **53**:587–599, 1980
8. Chamberlain MC: Adjuvant combined modality therapy for malignant meningiomas. **J Neurosurg** **84**:733–736, 1996
9. Chan RC, Thompson GB: Morbidity, mortality, and quality of life following surgery for intracranial meningiomas. A retrospective study in 257 cases. **J Neurosurg** **60**:52–60, 1984
10. Dolenc V: Direct microscopical repair of intracavernous vascular lesions. **J Neurosurg** **58**:824–831, 1983
11. Donnell MS, Meyer GA, Donegan WL: Estrogen-receptor protein in intracranial meningiomas. **J Neurosurg** **50**:499–502, 1979
12. Duma CM, Lunsford LD, Kondziolka D, et al: Stereotactic radiosurgery of cavernous sinus meningiomas as an addition or alternative to microsurgery. **Neurosurgery** **32**:699–705, 1993
13. Goldberg MA, Brugnara C, Dover GJ, et al: Hydroxyurea and erythropoietin therapy in sickle cell anemia. **Semin Oncol** **19** (Suppl 9):74–81, 1992
14. Goldsmith BJ, Wara WM, Wilson CB, et al: Postoperative irradiation for subtotally resected meningiomas. A retrospective analysis of 140 patients treated from 1967 to 1990. **J Neurosurg** **80**:195–201, 1994
15. Golnik KC, Miller NR, Long DL: Rate of progression and severity of neuropathologic manifestations of cavernous sinus meningiomas. **Skull Base Surg** **2**:129–133, 1992
16. Grunberg SM, Weiss MH, Spitz IM, et al: Treatment of unresectable meningiomas with the antiprogestosterone agent mifepristone. **J Neurosurg** **74**:861–866, 1991
17. Jääskeläinen J: Seemingly complete removal of histologically benign intracranial meningioma: late recurrence rate and factors predicting recurrence in 657 patients. A multivariate analysis. **Surg Neurol** **26**:461–469, 1986
18. Knosp E, Perneczky A, Koos WT, et al: Meningiomas of the space of the cavernous sinus. **Neurosurgery** **38**:434–444, 1996
19. Kotapka MJ, Kalia KK, Martinez AJ, et al: Infiltration of the carotid artery by cavernous sinus meningioma. **J Neurosurg** **81**:252–255, 1994
20. Lamberts SW, Tanghe HL, Avezaat CJ, et al: Mifepristone (RU 486) treatment of meningiomas. **J Neurol Neurosurg Psychiatry** **55**:486–490, 1992
21. Larson JJ, van Loveren HR, Balko MG, et al: Evidence of meningioma infiltration into cranial nerves: clinical implications for cavernous sinus meningiomas. **J Neurosurg** **83**:596–599, 1995
22. Lunsford LD: Contemporary management of meningiomas: radiation therapy as an adjuvant and radiosurgery as an alternative to surgical removal? **J Neurosurg** **80**:187–190, 1994
23. Marks SM, Whitewell HL, Lye RH: Recurrence of meningiomas after operation. **Surg Neurol** **25**:436–440, 1986
24. Maroon JC, Kennerdell JS, Vidovich D, et al: Recurrent sphenoidal meningioma. **J Neurosurg** **80**:202–208, 1994
25. Mirimanoff RO, Dosoretz DE, Linggood RL, et al: Meningioma: analysis of recurrence and progression following neurosurgical resection. **J Neurosurg** **62**:18–24, 1985
26. Newman SA: Meningiomas: a quest for the optimum therapy. **J Neurosurg** **80**:191–194, 1994
27. Petty AM, Kun LE, Meyer GA: Radiation therapy for incompletely resected meningiomas. **J Neurosurg** **62**:502–507, 1985
28. Poisson M, Magdelenat H, Foncin JF, et al: [Estrogen and progesterone receptors in meningiomas: a study in 22 cases.] **Rev Neurol** **136**:193–203, 1980 (Fr)
29. Schrell UM, Fahlbusch R, Adams EF: Meningiomas and neurofibromatosis for the oncologist. **Curr Opin Oncol** **6**:247–253, 1994
30. Schrell UM, Adams EF, Fahlbusch R, et al: Hormonal dependency of cerebral meningiomas. Part I: Female sex steroid receptors and their significance as specific markers for adjuvant medical therapy. **J Neurosurg** **73**:743–749, 1990
31. Schrell UM, Rittig MG, Anders M, et al: Hydroxyurea for treatment of unresectable and recurrent meningiomas. I. Inhibition of primary human meningioma cells in culture and in meningioma transplants by induction of the apoptotic pathway. **J Neurosurg** **86**:845–852, 1997
32. Schrell UM, Rittig MG, Kiesewetter F, et al: Hydroxyurea is a powerful inhibitor of meningioma cell growth. Evidence that hydroxyurea induces apoptosis in cultured meningioma cells and nude mice meningioma transplants. **Zentralbl Neurochir (Suppl)** **57**:38–39, 1996 (Abstract)
33. Sekhar LN, Møller AR: Operative management of tumors involving the cavernous sinus. **J Neurosurg** **64**:879–889, 1986
34. Simpson D: The recurrence of intracranial meningiomas after surgical treatment. **J Neurol Neurosurg Psychiatry** **20**:22–39, 1957
35. Zülch KJ: Tumors of meningeal and related tissues, in Zülch KJ (ed): **Brain Tumors: Their Biology and Pathology**, ed 3. Berlin: Springer-Verlag, 1986, pp 357–393

---

Manuscript received October 14, 1996.

Accepted in final form February 7, 1997.

Dr. Schrell is supported by a Career Development Award from the Ria Freifrau von Fritsch Stiftung.

Address reprint requests to: Uwe M. H. Schrell, M.D., Neurochirurgische Klinik der Universität Erlangen-Nürnberg, Schwabachanlage 6, 91054 Erlangen, Germany.